



US DEPARTMENT OF DEFENSE

BLAST INJURY RESEARCH PROGRAM COORDINATING OFFICE

Extremity Trauma Rehabilitation Development of a Large Animal Model for Heterotopic Ossification

Medical advancements in Operation Iraqi Freedom (OIF) and Operation Enduring Freedom (OEF) have led to a 92 percent survival rate of combat-injured Service members, a higher proportion than any previous military conflict. However, approximately 70 percent of war wounds have involved the musculoskeletal system, largely from the use of improvised explosive devices and rocket propelled grenades (Covey 2006, Isaacson, Potter, et al. 2016, Isaacson, Weeks, et al. 2010). In fact, there have been approximately 1,700 Service members who have major limb loss from the Iraqi/Afghanistan conflicts (Isaacson, Hendershot, et al. 2016). Given the intense nature of blast injuries, which require rapid tourniquet use, debridement and surgical intervention, heterotopic ossification (HO) has been reported to occur in approximately 63 percent of wounded Service members with limb loss or major extremity injuries (Forsberg et al. 2009, Forsberg and Potter 2010, Potter et al. 2007). Reports of recent OIF and OEF combat-related amputees with known HO have indicated that approximately 20-40 percent of affected patients required surgery to excise their bony masses (Potter et al. 2007, Potter et al. 2009, Tintle et al. 2012, Tintle et al. 2014). Symptomatic HO may delay rehabilitation regimens since it often requires modifications to prosthetic limb componentry and socket size.

To date, no empirical evidence has indicated a mechanism for quelling or preventing metabolically active HO. Correlative factors, such as gender, genetics, bioelectric signals, infection, and age have been associated with ectopic bone growth, but studies have often lacked histologic corroboration and advanced radiologic quantification (Bayley 1979, Goldman 1980, Hosalkar et al. 2009, Isaacson, Stinstra, et al. 2010, Kaplan et al. 1994, Potter et al. 2006, Wittenberg, Peschke, and Botel 1992). Ectopic bone formation has been induced in various animal models, however, the most practical approach, and one that is highly understudied, is the ovine (Anthonissen et al. 2014, Kan and Kessler 2011). Sheep have nearly identical mineral apposition rate levels and bone ingrowth into orthopaedic implants as that of humans and closely replicate the clinical condition (Bloebaum et al. 2007, Willie et al. 2004). Further, the development of a large animal model (ovine) will address what Forsberg et al. (2014) noted in Burned to the Bone that “one of the challenges preventing advances in this field has been the lack of robust animal models for HO.”

Extensive research at the Henry M. Jackson Foundation (Bethesda, Maryland), the Center for Rehabilitation Sciences (Bethesda, Maryland) and the University of Utah (Salt Lake City, Utah) by a team of military physicians, bone biologists, and rehabilitation experts have observed several common factors that may act as catalysts for inducing HO and create a model using the following: (1) an air impact device to cause localized bone and musculature trauma, (2) a tourniquet to induce hypoxia, (3) a wound vacuum to generate negative pressure, and (4) bioburden in the wound site to increase the likelihood for developing a localized and systemic infections. To date, the researchers have conducted 13 surgeries and demonstrated the ability to generate ectopic bone (Figure 1). The approach is being further refined





US DEPARTMENT OF DEFENSE
BLAST INJURY RESEARCH PROGRAM
COORDINATING OFFICE

to evaluate these factors individually and in combination to understand what exacerbates HO. Successful demonstration of this work will lead to evidence-based medicine, and be vital for combat casualty care and rehabilitation of Service members.

In conclusion, complications from HO delays rehabilitation for Service members. A robust translational model will explain the etiology of this pathological condition and help plan new clinical strategies to minimize ectopic bone formation and recurrence.

This research was funded by Defense Medical Research and Development Program, and is strategically aligned with Clinical and Rehabilitative Medicine Research Program. This award (W81XWH-16-2-0037) is managed by Congressionally Directed Medical Research Programs.

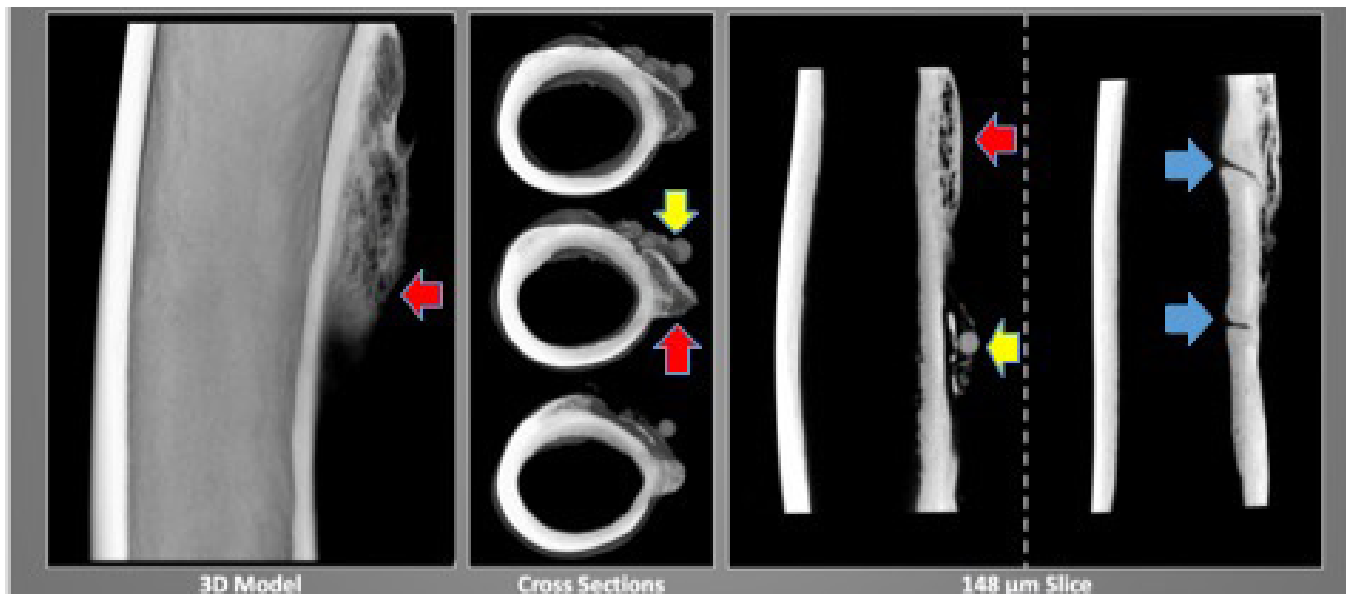


FIGURE 1: Micro CT images of an ovine at 24 weeks shows HO formation (red arrows). Note the reactive bone response around silica beads (yellow arrows) that were used to grow biofilms to simulate localized infections and locations where the bone was drilled to expose the medullary canal and generate localized trauma (blue arrows). (Figure used with permission from the authors)





US DEPARTMENT OF DEFENSE
BLAST INJURY RESEARCH PROGRAM
COORDINATING OFFICE

REFERENCES:

- Anthonissen, J., Ossendorf, C., Ritz, U., Hofmann, A., and Rommens, P. M. 2014. "Animal Models for Acquired Heterotopic Ossification." *Acta Orthop Belg* 80 (1):2-10.
- Bayley, S. 1979. "Funnybones: A Review of the Problem of Heterotopic Bone Formation." *Orthop Rev* 8 (1):113-20.
- Bloebaum, R. D., Willie, B. M., Mitchell, B. S., and Hofmann, A. A. 2007. "Relationship between Bone Ingrowth, Mineral Apposition Rate, and Osteoblast Activity." *J Biomed Mater Res A* 81 (2):505-14. doi: 10.1002/jbm.a.31087.
- Covey, D. C. 2006. "Combat Orthopaedics: A View from the Trenches." *J Am Acad Orthop Surg* 14 (10 Spec No.):S10-7.
- Forsberg, J. A., Pepek, J. M., Wagner, S., Wilson, K., Flint, J., Andersen, R. C., Tadaki, D., Gage, F. A., Stojadinovic, A., and Elster, E. A. 2009. "Heterotopic Ossification in High-Energy Wartime Extremity Injuries: Prevalence and Risk Factors." *J Bone Joint Surg Am* 91 (5):1084-91. doi: 10.2106/JBJS.H.00792.
- Forsberg, J. A., and Potter, B. K. 2010. "Heterotopic Ossification in Wartime Wounds." *J Surg Orthop Adv* 19 (1):54-61.
- Goldman, J. 1980. "Heterotopic Ossification in Spinal Cord Injuries." *Physiotherapy* 66 (7):219-20.
- Hosalkar, H., Pandya, N. K., Hsu, J., and Keenan, M. A. 2009. "What's New in Orthopaedic Rehabilitation." *J Bone Joint Surg Am* 91 (9):2296-310. doi: 10.2106/JBJS.I.00319.
- Isaacson, B. M., Hendershot, B. D., Messinger, S. D., Wilken, J. M., Rabago, C. A., Esposito, E. R., Wolf, E., Pruziner, A. L., Dearth, C. L., Wyatt, M., Cohen, S. P., Tsao, J. W., and Pasquina, P. F. 2016. "The Center for Rehabilitation Sciences Research: Advancing the Rehabilitative Care for Service Members with Complex Trauma." *Mil Med* 181 (S4):20-25. doi: 10.7205/MILMED-D-15-00548.
- Isaacson, B. M., Stinstra, J. G., MacLeod, R. S., Pasquina, P. F., and Bloebaum, R. D. 2010. "Developing a Quantitative Measurement System for Assessing Heterotopic Ossification and Monitoring the Bioelectric Metrics from Electrically Induced Osseointegration in the Residual Limb of Service Members." *Ann Biomed Eng* 38 (9):2968-78. doi: 10.1007/s10439-010-0050-2.
- Isaacson, B. M., Weeks, S. R., Pasquina, P. F., Webster, J. B., Beck, J. P., and Bloebaum, R. D. 2010. "The Road to Recovery and Rehabilitation for Injured Service Members with Limb Loss: A Focus on Iraq and Afghanistan." *US Army Med Dep J*:31-6.
- Kan, L., and Kessler, J. A. 2011. "Animal Models of Typical Heterotopic Ossification." *J Biomed Biotechnol* 2011:309287. doi: 10.1155/2011/309287.
- Kaplan, F. S., Craver, R., MacEwen, G. D., Gannon, F. H., Finkel, G., Hahn, G., Tabas, J., Gardner, R. J., and Zasloff, M. A. 1994. "Progressive Osseous Heteroplasia: A Distinct Developmental Disorder of Heterotopic Ossification. Two New Case Reports and Follow-up of Three Previously Reported Cases." *J Bone Joint Surg Am* 76 (3):425-36.
- Potter, B. K., Burns, T. C., Lacap, A. P., Granville, R. R., and Gajewski, D. 2006. "Heterotopic Ossification in the Residual Limbs of Traumatic and Combat-Related Amputees." *J Am Acad Orthop Surg* 14 (10 Spec No.):S191-7.
- Potter, B. K., Burns, T. C., Lacap, A. P., Granville, R. R., and Gajewski, D. A. 2007. "Heterotopic Ossification Following Traumatic and Combat-Related Amputations. Prevalence, Risk Factors, and Preliminary Results of Excision." *J Bone Joint Surg Am* 89 (3):476-86. doi: 10.2106/JBJS.F.00412.





US DEPARTMENT OF DEFENSE

BLAST INJURY RESEARCH PROGRAM COORDINATING OFFICE

- Potter, B. K., Granville, R. R., Bagg, M. R., Forsberg, J. A., Hayda, R. A., Keeling, J. J., Shrout, J. A., Ficke, J. R., Doukas, W. C., and Shawen, S. B. 2009. "Special Surgical Considerations for the Combat Casualty with Limb Loss." *Care of the combat amputee*. Falls Church, VA: Office of the Surgeon General:153-190.
- Tintle, S. M., Baechler, M. F., Nanos, G. P., Forsberg, J. A., and Potter, B. K. 2012. "Reoperations Following Combat-Related Upper-Extremity Amputations." *J Bone Joint Surg Am* 94 (16):e1191-6. doi: 10.2106/JBJS.K.00197.
- Tintle, S. M., Shawen, S. B., Forsberg, J. A., Gajewski, D. A., Keeling, J. J., Andersen, R. C., and Potter, B. K. 2014. "Reoperation after Combat-Related Major Lower Extremity Amputations." *J Orthop Trauma* 28 (4):232-7. doi: 10.1097/BOT.0b013e3182a53130.
- Willie, B. M., Bloebaum, R. D., Bireley, W. R., Bachus, K. N., and Hofmann, A. A. 2004. "Determining Relevance of a Weight-Bearing Ovine Model for Bone Ingrowth Assessment." *J Biomed Mater Res A* 69 (3):567-76. doi: 10.1002/jbm.a.30038.
- Wittenberg, R. H., Peschke, U., and Botel, U. 1992. "Heterotopic Ossification after Spinal Cord Injury. Epidemiology and Risk Factors." *J Bone Joint Surg Br* 74 (2):215-8.

